

Hands On

Reports on the Rheumatic Diseases | Series 6 | **Spring 2012** | Hands On No 11

The upper limb in primary care Part 1: Upper and lower arm, elbow

Richard Smith

Consultant Rheumatologist, Salisbury NHS Foundation Trust

Editorial

Upper limb problems are very rewarding to manage in primary care. They are readily assessed using clinical skills and mostly can be treated without referral to secondary care. In order to diagnose successfully it is necessary to take a good history and have a grasp of basic anatomy and knowledge of some simple clinical tests.

Richard Smith has great experience in rheumatology and musculoskeletal medicine, both practically and from his many teaching roles. He is therefore ideally placed to write this article about upper limb problems. He was asked to approach this as if he were working in primary care and the result is a very helpful and practical guide.

Simon Somerville

Note that a second upper limb report addressing the **wrist and hand** is in preparation. The **shoulder** was covered in: Hands On (Series 5) No 14; 2008 Feb (see 'Further reading').

Introduction

Disorders of the upper limb are common in general practice. Morbidity surveys in primary care have found an annual incidence of first consultation for upper limb disorders of approximately 25 per 1000 person years, with rates increasing from 25 to 45 years of age and then levelling off.¹ This report will concentrate on the common conditions of the elbow and surrounding structures encountered in primary care and will present them topographically. Emphasis will be placed upon how to make an accurate diagnosis, how to manage the condition within primary care, and when to refer for specialist advice. In-depth information about rheumatoid arthritis, osteoarthritis and shoulder disorders is covered in previous issues of Hands On – see 'Further reading'.

History

Upper limb disorders may present either acutely (with an obvious history of trauma) or chronically. Chronic conditions will often have a history

TABLE 1. Risk factors for upper limb disorders.

| Intrinsic | Extrinsic |
|-------------------------------------------------------------------------------------------------------------------------------------------------------------------------------------------------------------------------------------------------------------------------------------------------------------------------|-------------------------------------------------------------------------------------------------------------------------------------------------------------------|
| <ul style="list-style-type: none">• Malalignment• Muscle imbalance• Muscle weakness• Hypo/hypermobility• Systemic illness (e.g. inflammatory arthritis, diabetes, osteoporosis)• Previous injury• Sex, size, body composition• Medications | <ul style="list-style-type: none">• Faulty ergonomics• Inappropriate equipment• Excessive intensity• Repetitive activity |

of preceding, exacerbating or causative factors resulting in chronic microtrauma to local structures. In both cases a careful history is essential. Without addressing the underlying factors leading to the presentation, any management of an upper limb disorder is doomed to failure.

These factors are often termed intrinsic (factors relating to oneself) or extrinsic (factors relating to the environment). A classic example of an extrinsic factor is faulty ergonomics in work-related upper limb disorders. Table 1 summarises the important intrinsic and extrinsic factors that should be considered in patients with upper limb disorders.

A good history should suggest the diagnosis which may then be confirmed by clinical examination and/or appropriate investigations. It should be remembered that many upper limb disorders are clinical diagnoses which do not require specific investigations.

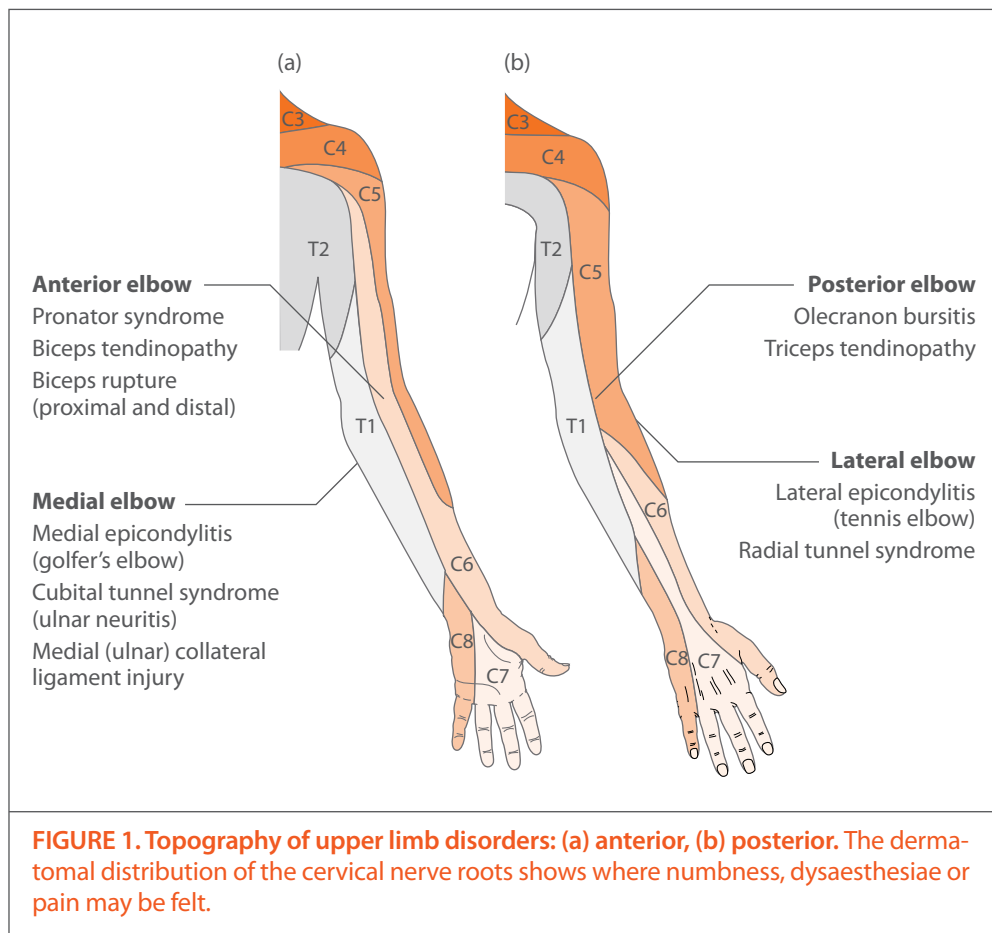
Important points in the history include:

- Diurnal variation
 - Inflammatory conditions such as rheumatoid arthritis are worse in the morning and often improve with activity
 - Degenerative or overuse conditions such as osteoarthritis or epicondylitis are worse at the end of the day and are exacerbated by activity
- Heat or redness strongly suggest inflammation or infection
- Swelling may be objective (visible swelling with tight finger-rings) or subjective – neuropathic disorders may make the limb ‘feel’ swollen (akin to the feeling of swelling in the mouth after dental local anaesthetic)
- Pain site, type, radiation, onset and resolution in relation to exercise or activity

- Sleep disturbance (neuropathic arm pain is often associated with nocturnal pain and disturbed sleep)
- Precipitant and relieving factors
- Demands of specific sport, exercise, hobbies or job. It is appreciated that not all physicians can have expert knowledge of specific sports or specific work ergonomics. It is quite reasonable to ask the patient what their job or sport entails and even to demonstrate it during the consultation. It should also be remembered that although everyday activities may exacerbate an upper limb disorder they may not be the original causative agent. To determine whether a condition is work-related it is often helpful to ask whether the pain is worse during the week- (or working) day compared to the weekend and holidays.

Examination

It is useful to ask the patient to point to the site of maximal pain and discomfort. A working knowledge of the anatomy of the upper limb is essential as pain may originate from any of the soft tissues, joint or bone, or be referred from proximal or distal structures, or be part of a radiculopathy. Figure 1 shows some of the more common diagnoses related to the area and the dermatomal distribution of the upper limb. A golden rule of musculoskeletal examination is always to examine the joints above and below the site of pain to exclude referred pain. If the history is suggestive, i.e. neck pain radiating down the arm, with or without pins and needles, numbness and/or weakness, the cervical spine should also be examined. Inflammation or trauma to the brachial plexus may also, rarely, present with upper limb and shoulder pain. In brachial plexus lesions



there may be abnormal neurological findings not consistent with dermatomal or myotomal distribution. A nerve conduction study is useful in determining a brachial plexus lesion.

Infection

Any structure in the upper limb can become infected. This includes joints and skin. There may or may not be an obvious entry point (cut or abrasion). Joints can become infected secondary to haematological spread (in sepsis or endocarditis). The C-reactive protein (CRP) and white cell count (WCC) would be expected to be elevated; however if infection is suspected an urgent referral for joint aspiration and appropriate antimicrobial therapy is recommended.

ANTERIOR ELBOW

Radicular pain from C4, C5 nerve roots may cause pain or dysaesthesiae above the elbow. C4 and C5 radiculopathy may also be accompanied by weakness of shoulder abduction and reduced biceps reflex.

The common structures that cause anterior elbow pain are the biceps muscle and tendon. The biceps muscle is so called because it has two origins (short and long head) and two muscle bodies. The short head of biceps originates from the coracoid process of the scapula and is rarely affected by tendinopathy or injury. The long head of biceps originates from within the glenohumeral joint capsule, has a long protracted course emerging from the shoulder joint through the bicipital groove, and is prone to both tendinopathy and rupture. Tendinopathy is painful whereas rupture, which is normally complete, may be painless.

Biceps tendinopathy

Biceps tendinopathy classically presents with a dull ache in the anterior shoulder. It is caused by degeneration of the tendon often seen in athletes involved in repetitive overhead motion or due to the normal ageing process. Biceps tendinopathy is commonly accompanied by rotator cuff tears or SLAP (superior labrum anterior to posterior) lesions. Repetitive overhead motion of the arm initiates or exacerbates the symptoms.

Clinical examination includes point tenderness on the biceps tendon found overlying the anterior part of the shoulder in the groove between anterior deltoid and pectoralis major. Pain may be exacerbated by resisted straight arm flexion and external rotation of the arm at 90° (Speed's test) or by resisted supination with the elbow at 90° (Yergason's test).

Investigation The diagnosis of biceps tendinopathy should be made clinically. Ultrasound can be useful to confirm a clinical diagnosis or to guide a therapeutic injection of lidocaine and hydrocortisone. The tendon sheath is continuous with the glenohumeral joint, and therefore fluid in the tendon sheath may be secondary to a glenohumeral joint effusion. If ultrasound is requested the glenohumeral joint and rotator cuff should also be assessed at the same time.

Magnetic resonance imaging (MRI) may be useful in picking up any intra-articular pathology such as a SLAP lesion and should be considered in athletes participating in throwing sports presenting with shoulder pain and biceps tendinopathy.

Management Initial management includes rest, ice, oral analgesics and physical therapy. Corticosteroid injections into the biceps tendon sheath may be administered but do carry with them the risk of long head tendon rupture, especially in elderly patients with a degenerative tendon.

Surgery should only be considered if conservative measures fail or if there is severe damage to the biceps tendon.

Biceps tendon rupture

Proximal biceps rupture may be a consequence of chronic inflammation as occurs in rheumatoid arthritis or due to excessive loading or rapid stress upon the tendon such as in weightlifting. The long head of biceps may rupture due to sudden loading (which may be painful and associated with an audible pop) or may occur asymptotically and painlessly.

Examination may reveal bruising over the proximal anterior arm. There may be an obvious swelling in the arm caused by the contracted biceps muscle ('Popeye sign') which does not move with supination. Ludington's test (hands clasped

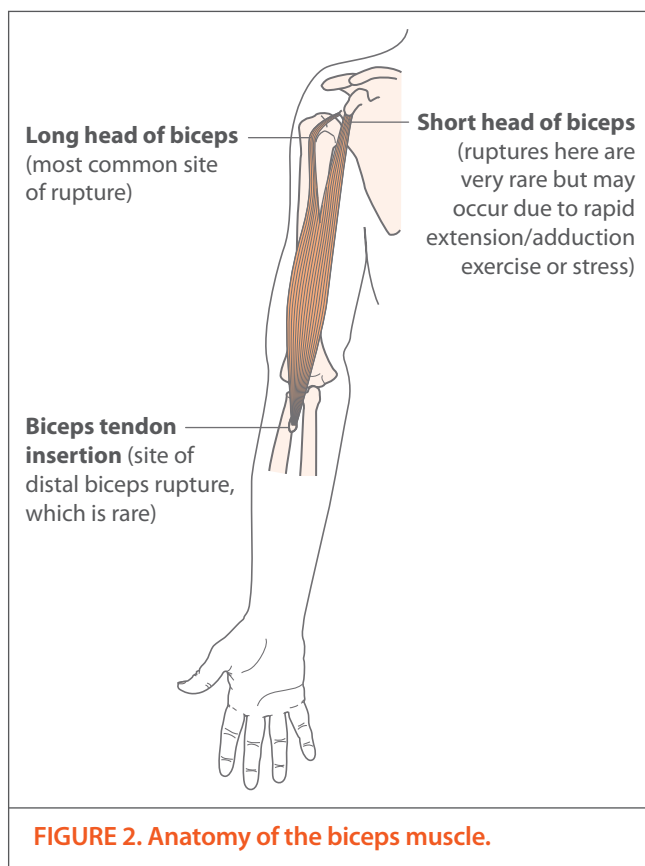


FIGURE 2. Anatomy of the biceps muscle.

behind the head and the biceps muscles flexed) is useful to look for asymmetry in muscle bulk between both biceps. There may be tenderness on palpation along the course of the biceps tendon and muscle belly, including the bicipital groove, with the arm placed in 5–10° of internal rotation. Assess power of the upper limb and range of movement (ROM) of the shoulder and elbow. Proximal biceps rupture results in approximately 20% forearm flexion loss but more significant loss of forearm supination.

Distal biceps rupture (at the tendon insertion) is rare, occurring in sports such as weightlifting, and always requires urgent surgical referral for repair.

Investigation In most cases, proximal and distal ruptures can be detected on the basis of history and physical examination alone. Plain x-rays may reveal hypertrophic spurring or bony irregularities that increase the risk of rupture and so support a clinical diagnosis.

Ultrasonography and MRI of the anterior shoulder may also be useful in confirming the diagnosis, as they will show an absence of the tendon in the bicipital groove.

Management The management of proximal biceps rupture is dependent upon the individual clinical case. In elderly patients with a proximal biceps rupture a conservative approach can be adopted as most will become asymptomatic after 4–6 weeks. If painful, the initial management should be the standard RICE (rest, ice, compression and elevation) approach combined with physiotherapy when the acute swelling has settled. In athletes or younger patients surgical referral should be considered.

Pronator syndrome

Pronator syndrome (pronator teres syndrome) is a compression neuropathy of the proximal median nerve as it passes between the two heads of the pronator muscle in the proximal forearm. This condition is rare compared with more distal compression of the median nerve (carpal tunnel syndrome). Repetitive use of the pronator muscle as seen in people on factory assembly lines (especially hammering) and in some musicians is a key predisposing factor. The condition presents with pain over the proximal median nerve and sensory disturbance in the lateral three and a half fingers of the palmar aspect of the hand (median nerve distribution). There may be weakness of the flexor pollicis longus, the flexor digitorum profundus of the index finger and the pronator quadratus.

Investigation The condition can be made clinically. The key finding is tenderness over the proximal forearm, aggravated by resisted pronation of the forearm (opposite movement to Yergason's test). The weak flexor muscles of the thumb and index finger may lead to a weak pincer movement and there may be sensory loss in the median nerve distribution of the hand. Tinel's test at the wrist should be negative but positive over the proximal forearm. Phalan's test should be negative. A nerve conduction study is useful in excluding the more common carpal tunnel syndrome.

Management The mainstay of treatment is physiotherapy. Referral for guided corticosteroid injections or surgical decompression should be considered in resistant cases or where there is significant weakness.

POSTERIOR ELBOW

C7 lesions may present with posterior lateral arm pain, weakness of triceps and loss of the triceps reflex.

Olecranon bursitis (student's elbow)

The olecranon bursa is located over the extensor aspect of the proximal part of the ulna and functions to provide a mechanism for the skin to glide freely over the olecranon process, thereby preventing tissue tears. Olecranon bursitis is the most common superficial bursitis and may be caused by traumatic, inflammatory and infectious processes. The most common cause is idiopathic. The traditional term for this condition is 'student's elbow'.

Olecranon bursitis may present unilaterally or bilaterally as part of an inflammatory condition such as gout, pseudogout or rheumatoid arthritis.

Investigation The diagnosis is made clinically. If there is any doubt about the diagnosis then ultrasound will clearly show fluid within the bursa.

Clinical tip: Look for tophi or rheumatoid nodules. In patients with suspected gout an olecranon bursa may be an easily accessible site to aspirate and confirm the diagnosis by demonstrating crystals.

Management The management of this common condition should start with simple RICE and avoidance of exacerbating factors. Aspiration can be performed for cosmetic reasons or if the bursa is sufficiently large to interfere with everyday activity. The application of a Tubigrip™ post-aspiration may help prevent rapid reaccumulation of fluid within the bursa.

If infection is suspected than aspiration for gram stain, culture and sensitivity is mandatory.

Triceps tendinopathy

The triceps (so called because of its three muscular bodies) inserts into the ulna. Triceps tendinopathy is less common than biceps tendinopathy but may occur due to repetitive or prolonged

activities placing strain on the triceps tendon, such as repetitive pushing activities or straightening the elbow against resistance (e.g. performing push-ups or dips). Occasionally, it may occur suddenly due to a high force going through the triceps tendon beyond what it can withstand.

Investigation The diagnosis is made clinically. There should be discomfort over the posterior aspect of the elbow. The elbow joint is not involved and the olecranon bursa should not be inflamed. Pain is reproduced by resisted arm extension. Ultrasound can confirm the diagnosis and an x-ray may show calcification at the triceps insertion in more chronic cases.

Management The management of this condition is initial rest followed by physiotherapy.

LATERAL ELBOW

Radicular pain from C5 and C6 may present with lateral elbow pain. There may be accompanying weakness of elbow flexion and reduced or absent biceps reflex with a C6 radiculopathy, while C5 pathology may result in weakness of shoulder abduction.

The most common cause of lateral elbow pain is lateral epicondylitis or 'tennis elbow'.

Lateral epicondylitis (tennis elbow)

Lateral epicondylitis is a common disorder of the elbow, affecting 1.3% of the population. It is a tendinopathy of the common extensor origin of the lateral elbow. It is thought to result from over-use of the extensor carpi radialis brevis and the extensor digitorum communis.

The condition most commonly occurs in patients who perform repetitive wrist movements or strong gripping. Tennis players can be affected, especially with the backhand stroke that leads to excessive loading of the tendons at the common extensor origin. In the general population, people who are usually sedentary and begin exercising at a gym, painting, or lifting a new baby may also be affected.

The clinical examination should reveal point tenderness over the lateral aspect of the elbow at the origin of the common extensor origin. This

point can be localised by asking the patient to resist dorsiflexion (extension) at the wrist. This manoeuvre should also be painful. The elbow joint itself is not affected, i.e. the elbow should have a full ROM and no demonstrable effusion (loss of the indentations either side of the olecranon).

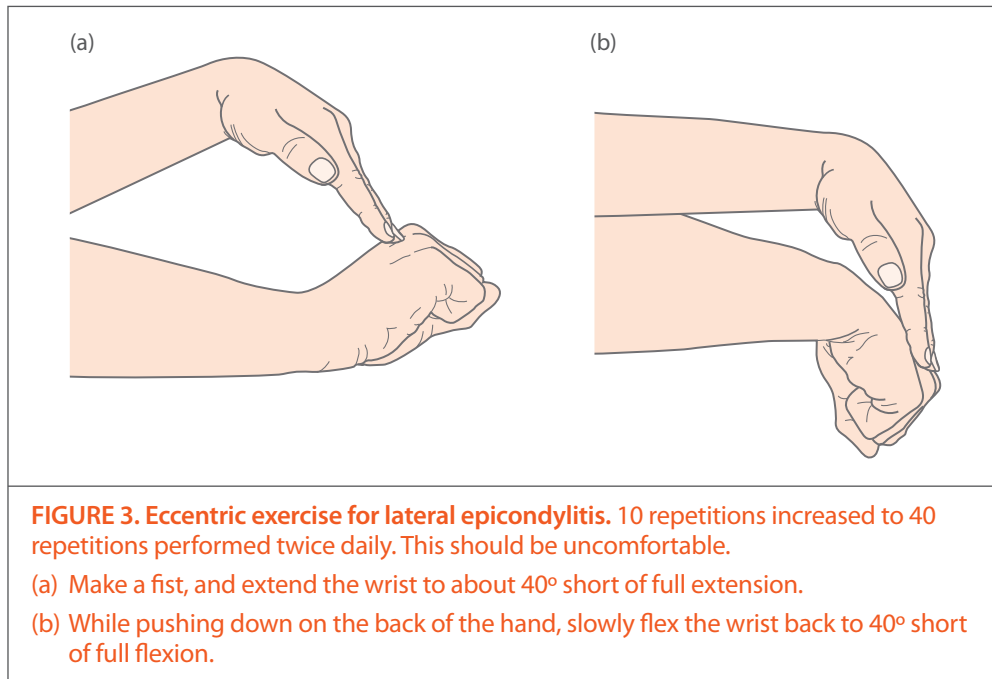
Clinical tip: A useful screening test for lateral epicondylitis is the 'pick up the back of a chair test'. The ability to pick up the back of a chair with the palmar surface of the hand facing down virtually excludes lateral epicondylitis.

Investigation Lateral epicondylitis is a clinical diagnosis. However, ultrasound is the preferred investigation of choice where there is any doubt about the diagnosis or if patients fail to respond to conservative therapy. Ultrasound can also be used for guided injections.

Management The treatment of lateral epicondylitis aims to reduce pain, increase strength and improve quality of life of the patient, while keeping side-effects of treatment to a minimum. It is essential that any exacerbating factors be addressed as part of any active treatment. Strapping, epicondyle supports or taping may offer temporary relief; however the mainstay of treatment is ergonomic advice and eccentric exercises first line followed by supervised physiotherapy if unsuccessful.

- **Physiotherapy: rehabilitation and graduated loading** The aim of physiotherapy is to exercise (load) the tendon as close to its limits as possible, without exceeding them. Eccentric (lengthening only) exercises reduce pain and improve function and are commonly used in other forms of tendinopathy (such as chronic Achilles tendinopathy).
- **Glyceryl trinitrate (GTN) patches (unlicensed use)** Topical GTN (nitroglycerin) patches² provide a localised source of nitric oxide to the tendon. Nitric oxide is essential to tendon healing. Eccentric loading combined with GTN patches improves outcomes by 30% compared to exercise alone.

Administration of topical GTN involves the use of a 5 mg GTN matrix patch cut into quarters,



providing a dose of 1.25 mg which should be applied daily to the affected site. Side-effects include dizziness and headaches through vasodilation-induced hypotension. GTN should be prescribed for 3 months and combined with eccentric loading.

- **Injection therapy** Cortisone injections are beneficial in the short term (6 weeks) but may be harmful in the longer term (more than 3 months).³ The short-term outcome may of course be more important than the longer-term for some patients such as a tennis player in their final Grand Slam tournament. However in most patients long-term prognosis is important so cortisone should be avoided. Future research with ultrasound may help identify which patient subgroup may benefit from cortisone injections.

Injections of autologous blood and platelet-rich products are sometimes administered by musculoskeletal experts for resistant cases of lateral epicondylitis. The data for this treatment is not conclusive. Currently the National Institute for Health and Clinical Excellence (NICE) guidance supports the administration of autologous blood with strict clinical audit follow-up and data accumulation.⁴

Consider specialist referral or surgery if symptoms persist.

Radial tunnel syndrome

This condition presents with similar lateral elbow pain to lateral epicondylitis; however the site of maximal pain lies 4 finger breadths distal to the common extensor origin. The condition is caused by entrapment of the posterior interosseus nerve within the radial tunnel. The posterior interosseus nerve is a branch of the radial nerve. It is a pure motor nerve with no sensory component, hence – unlike other entrapment neuropathies – there is no pins and needles or sensory deficit. There may be weakness of digital extensors.

Investigation Radial tunnel syndrome is a clinical diagnosis and should be considered in patients presenting with resistant lateral epicondylitis. Nerve conduction and electromyography studies have high specificity but low sensitivity.

Management Management involves avoidance of aggravating factors and physiotherapy. Resistant cases should be referred for surgical decompression of the radial tunnel.

MEDIAL ELBOW

Radiculopathy from C8 and T1 may cause medial elbow pain. T1 radiculopathy is often associated with loss of sensation over the medial forearm. If T1 radiculopathy is suspected the patient should be examined to exclude Horner's syndrome.

The most common cause of medial elbow pain is medial epicondylitis ('golfer's elbow'). This condition is significantly less common than lateral epicondylitis, hence the lack of large randomised controlled clinical trials. The key differential diagnoses are cubital tunnel syndrome and medial ligament strain. These conditions can occasionally coexist.

Medial epicondylitis (golfer's elbow)

Medial epicondylitis is an overuse injury affecting the flexor-pronator muscles (i.e. pronator teres, flexor carpi radialis, palmaris longus) at their origin on the anterior medial epicondyle of the humerus. Onset can be related to occupation (e.g. consistent use of a tool such as a hammer, or in baseball when throwing a pitch).

Examination should reveal point tenderness of the medial aspect of the elbow over the common flexor origin. This point can be found by palpating the elbow with the wrist held in resisted palmar flexion. Discomfort with this manoeuvre is confirmatory. Neurological examination of the upper limb should be normal. The joint is not involved so ROM should not be affected.

Investigation The diagnosis is made clinically. Ultrasound is the investigation of choice if there is any doubt over the diagnosis. A nerve conduction study can be useful in excluding cubital tunnel syndrome.

Management Management of medial epicondylitis involves RICE and avoidance of aggravating factors. Strapping, braces and taping may offer temporary relief. Patients should be referred for physiotherapy. There is no evidence for eccentric loading of the common flexor tendons; however because the pathology is identical to the more common lateral epicondylitis this would seem a prudent approach to physiotherapy. Corticosteroid injections may be administered with an efficacy similar to that for lateral epicondylitis; however care must be taken to avoid damaging the ulnar nerve within the cubital tunnel.

Clinical tip: Psoriatic arthritis and ankylosing spondylitis may present with resistant, recurrent or even bilateral epicondylitis (enthesitis). Fibromyalgia may also present with pain but no inflammation over both lateral epicondyles.

Cubital tunnel syndrome (ulnar neuritis)

Entrapment of the ulnar nerve within the cubital tunnel and subsequent inflammation may present with medial elbow pain, hand weakness (positive Froment's and Wartenberg's signs – see Figure 4) and dysaesthesiae or pins and needles radiating down the medial forearm.

Examination may reveal a positive Tinel's test (medial elbow pain and 4th and 5th digit pins and needles upon tapping the cubital tunnel over the medial aspect of the elbow ('funny bone')). In isolated cubital tunnel syndrome, the elbow joint should have a normal ROM; however this condition can also be seen in rheumatoid arthritis or osteoarthritis of the elbow joint where the joint itself may also be affected.

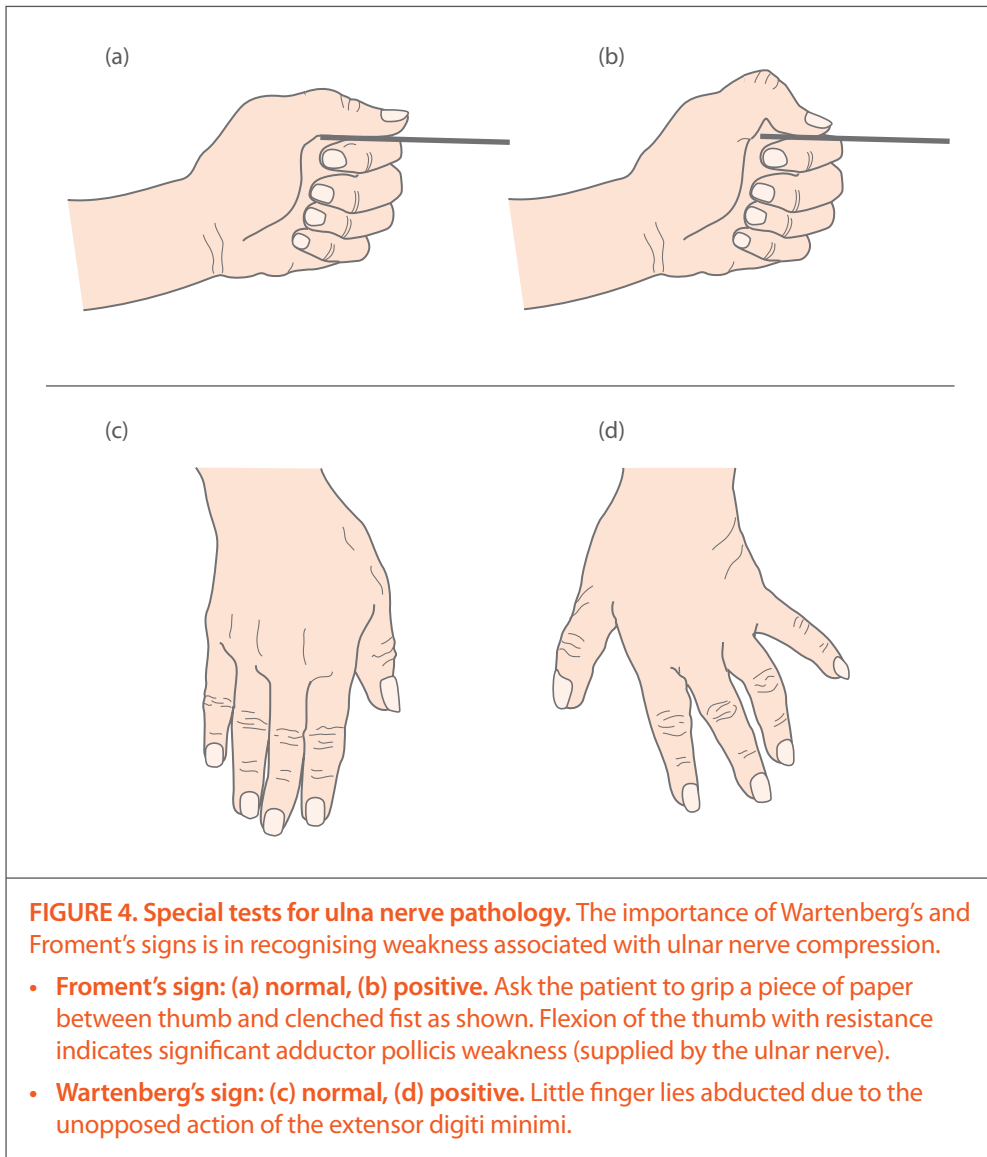
Investigation The diagnosis of cubital tunnel syndrome can be made clinically but should be confirmed with a nerve conduction study. A plain x-ray will show if there is bony impingement of the cubital tunnel. Ultrasound may show swelling of the ulnar nerve and is useful in confirming the position of the ulnar nerve before surgery.

Management Patients with mild sensory symptoms may benefit from ergonomic advice and physiotherapy. Ultrasound-guided injections of hydrocortisone may offer temporary relief. Patients presenting with weakness (positive Froment's and Wartenberg's) should be referred for surgical decompression.

Medial (ulnar) collateral ligament injury

Elbow ulnar collateral ligament insufficiency is commonly seen in sports participants involved in overarm-throwing sports such as cricket, baseball and tennis. Patients present with medial elbow pain. The condition is usually chronic and there may be a history of long-term deterioration in the ability to throw. Trauma and elbow dislocation injuries may result in acute damage to the ulnar ligament.

The ulnar ligament is composed of three bands: anterior, posterior and transverse. The anterior band arises from the medial epicondyle and inserts on the proximal ulna. Examination reveals medial elbow tenderness, approximately 2 cm distal to the medial epicondyle, with or without



swelling. Pain may be reproduced by asking the patient to make a clenched fist or by placing the elbow in a valgus stress in 25° of flexion (elbow abduction stress test). The affected side should be compared with the contralateral elbow for laxity.

Investigation The diagnosis can be made clinically. An x-ray is useful in excluding other causes of elbow pain (osteoarthritis, avulsion fractures, loose bodies). MRI is the investigation of choice.

Management Acute injuries should be referred for surgical intervention. Chronic injuries should be referred for physiotherapy. The patient should stop all throwing or exacerbating factors until pain-free. Surgical referral should be considered in chronic injuries after failed physiotherapy with appropriate rest or if the elbow is unstable.

Conclusion

Upper limb disorders are common. They may be related to work or exercise or be due to simple degenerative causes, and may present acutely or chronically. Pain in the upper limb may be localised, referred or radicular in nature. It is hoped that this topographical structured approach to the more common upper limb disorders will enable the physician to make an accurate diagnosis, recognise the predisposing or causative factors, and treat both in an holistic manner.

Acknowledgement

I am grateful for the help of my former colleague Dr Rakhi Seth in the preparation of this report.

References

1. Royal College of General Practitioners. Third National Morbidity Survey in General Practice 1980–1. Series MB5 No 1. London: HMSO; 1986.
2. Murrel GA. Using nitric oxide to treat tendinopathy. *Br J Sports Med* 2007;41(4):227-31.
3. Bisset L, Beller E, Jull G, Brooks P, Darnell R, Vicenzino B. Mobilisation with movement and exercise, corticosteroid injection, or wait and see for tennis elbow: randomised trial. *BMJ* 2006;333(7575):939.
4. National Institute for Health and Clinical Excellence. Autologous blood injection for tendinopathy. *Interventional Procedure Guidance* 279. London: NICE; 2009 Jan.

Further reading

Brukner P, Khan K (ed). *Clinical sports medicine*. 3rd edn. Sydney: McGraw Hill; 2006.

Hutson M, Ellis R (ed). *Textbook of musculoskeletal medicine*. Oxford University Press; 2006.

Peterson L, Renström P. *Sports injuries: their presentation and treatment*. 3rd edn. London: Martin Dunitz 2001.

Arthritis Research UK reports (all accessible via the *Hands On archives* page: <http://www.arthritisresearchuk.org/health-professionals-and-students/reports/reports-archives/hands-on.aspx>):

- Deighton C, Luqmani R. The NICE and BSR guidelines on the management of rheumatoid arthritis. *Hands On* (Series 6) No 4; 2009 Autumn.
- Mitchell C. Management of shoulder disorders in primary care. *Hands On* (Series 5) No 14; 2008 Feb.
- Porcheret M, Healey E, Dziedzic K et al. Osteoarthritis: a modern approach to diagnosis and management. *Hands On* (Series 6) No 10; 2011 Autumn (plus Information and exercise sheet).

Continuing professional development (CPD) task

- Brush up your knowledge of clinically relevant anatomy of the upper limb. Develop a scheme to quickly assess the myotomes and dermatomes.
- Check that you have ready access to information, either paper-based or online, to give to patients about the treatment of lateral epicondylitis, especially with respect to self-help exercises.

STarT Back – one size doesn't fit all

The Keele STarT Back approach developed by the Arthritis Research UK Primary Care Centre uses a simple clinical tool to stratify patients according to their risk of developing chronic back pain and then direct them towards treatment appropriate to their level of risk. The results recently published in *The Lancet* show that this approach both gives better outcomes for patients and is more cost-effective.

www.keele.ac.uk/sbst/

In connection with this, Keele is hosting a free conference on **17 April 2012** with workshops for clinicians and commissioners:

Implementing stratified care for back pain Implications for commissioning

www.keele.ac.uk/sbst/training

Step-by-step help for inflammatory arthritis

Have your patients got the 'S Factor'?

- Early-morning joint **S**tiffness lasting over 30 minutes
- Persistent **S**welling of one joint or more
- Pain when joints are **S**queezed

It could be inflammatory arthritis and delay can cause long-term disability.

Only 10% of people were confident that they knew the symptoms of inflammatory arthritis, according to a survey conducted by the two leading arthritis charities, Arthritis Research UK and the National Rheumatoid Arthritis Society. These charities have launched the **Inflammatory Arthritis Pathway**, an online step-by-step guide to a person's journey with inflammatory arthritis:

www.arthritisresearchuk.org/arthritis-information/inflammatory-arthritis-pathway.aspx

Would you prefer to receive our reports in electronic format?

If you enjoy Hands On, Synovium or Topical Reviews but would prefer to view them electronically you can now opt to receive a free email notification as soon as new issues are published.

In addition, **Topical Reviews** will change to electronic-only distribution after the Summer 2012 issue, so to keep receiving Topical Reviews after this time **you must sign up to our email notification list**. To do this please go to www.arthritisresearchuk.org/reportsmailinglists.

Once you have entered your details you will, at the time of the next issues, receive an email containing links direct to the latest Hands On, Synovium and Topical Reviews, plus a link to the full on-line archive of back issues.

Postal distribution of Hands On and Synovium

If you are a GP please note that Hands On and Synovium are now distributed by post as inserts with the RCGP's *British Journal of General Practice* rather than via our previous distribution list. Other, non-GP, audiences will continue to receive these items via our usual mailing house.

If you **are** a GP and you do not receive the issues by post when you previously have done so, we would like to know – please sign up to our postal mailing list or email notification list to keep receiving your copies (see the link above).

Copeman House, St Mary's Court
St Mary's Gate, Chesterfield
Derbyshire S41 7TD

Tel 0300 790 0400 **Fax** 01246 558007
Email enquiries@arthritisresearchuk.org
www.arthritisresearchuk.org

Registered Charity England and Wales no. 207711,
Scotland no. SC041156

 **Arthritis
Research UK**

Providing answers today and tomorrow

This issue of Hands On can be downloaded from the Arthritis Research UK website:
www.arthritisresearchuk.org/handson.

Hard copies of this and all our other publications are obtainable via the on-line ordering system: www.arthritisresearchuk.org/shoppublications, by email: arthritisresearchuk@bradshawsdirect.co.uk, or from: Arthritis Research UK Trading Ltd, James Nicolson Link, Clifton Moor, York YO30 4XX.

Medical Editor: Simon Somerville.
Project Editor: Frances Mawer
(f.mawer@arthritisresearchuk.org).

ISSN 1741-833X. Published 3 times a year by Arthritis Research UK.

