

# Relationship Between Femoral Anteversion and Findings in Hips With Femoroacetabular Impingement

LEANDRO EJNISMAN, MD; MARC J. PHILIPPON, MD; PISIT LERTWANICH, MD; ANDREW T. PENNOCK, MD; MACKENZIE M. HERZOG, BA; KAREN K. BRIGGS, MPH; CHARLES P. HO, MD, PHD

## abstract

Full article available online at [Healio.com/Orthopedics](http://Healio.com/Orthopedics). Search: 20130222-17

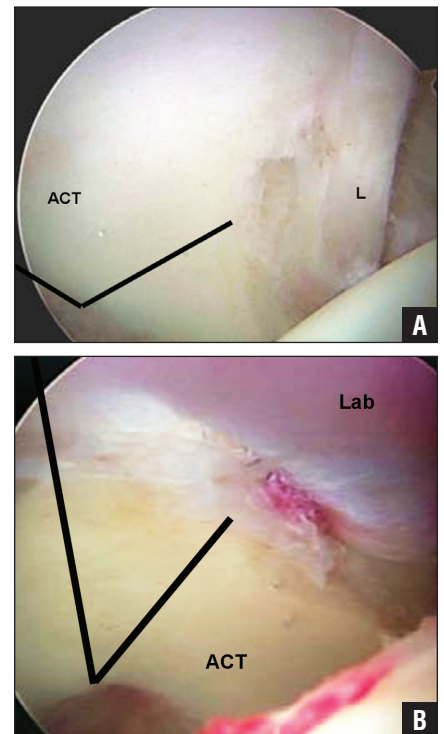
The purpose of this study was to investigate the relationship between femoral neck version and pre- and intraoperative findings in hips with femoroacetabular impingement (FAI). The authors retrospectively reviewed prospectively collected data on 188 patients (204 hips) who underwent hip arthroscopy for FAI and labral pathology. Femoral version was measured on magnetic resonance imaging by a fellowship-trained musculoskeletal radiologist. The study group comprised 100 men and 88 women with a mean age of 35 years (range, 18 to 62 years). Mean femoral version was 9° (range, -10° to 27°). No relationship was found between femoral version and patient demographics (ie, age, sex, weight, height, and body mass index). A significant correlation was found between version and degrees of external rotation ( $r = -0.208$ ;  $P = .027$ ) and internal rotation ( $r = 0.231$ ;  $P = .002$ ) on physical examination. Patients with femoral version less than 5° had significantly increased external rotation ( $P = .027$ ). Intraoperative findings demonstrated that femoral version greater than 15° was related to larger labral tears that averaged approximately 38 mm in size, whereas patients with anteversion less than 5° had tear sizes measuring 30 mm and patients with angles between 5° and 15° had tear sizes averaging 34 mm ( $P = .008$ ). Hips with femoral version greater than 15° were 2.2 times more likely (95% confidence interval, 1.2 to 4.1) to have labral tears that extended beyond the 3 o'clock position, denoting more anterior tears. Hips in which a psoas release was performed had higher version angles (8° vs 11°;  $P = .023$ ).

*The authors are from Steadman Philippon Research Institute (LE, MJP, MMH, KKB, CPH); and The Steadman Clinic (MJP), Vail, Colorado; the Department of Surgery (MJP), Faculty of Health Sciences Hamilton, McMaster University, Ontario, Canada; the Department of Orthopaedic Surgery (PL), Faculty of Medicine Siriraj Hospital, Mahidol University, Bangkok, Thailand; and the Department of Orthopaedic Surgery (ATP), Rady Children's Hospital and Health Center, University of California, San Diego, California.*

*Dr Ejnisman received a scholarship that provided grants from the Instituto Brasil de Tecnologias da Saúde. Dr Philippon is a board member/owner/officer/committee appointment of Arthrocare; receives royalties from Smith & Nephew, Arthrocare, DonJoy, and Bledsoe; is a paid consultant for Smith & Nephew; and has stock or stock options in Smith & Nephew. Drs Philippon, Pennock, and Ho and Mss Herzog and Briggs receive research or institutional support from Smith & Nephew, Ossur, Arthrex, and Siemens.*

*Correspondence should be addressed to: Marc J. Philippon, MD, Steadman Philippon Research Institute, Attn: Center for Outcomes-based Orthopaedic Research, 181 W Meadow Dr, Ste 1000, Vail, CO 81657 (drphilippon@sprivail.org).*

*doi: 10.3928/01477447-20130222-17*



**Figure:** Arthroscopic image of a labral tear in the anterior position extending past the 3-o'clock position (A) compared with a tear in the 12- to 2-o'clock position (B). Abbreviations: ACT, acetabulum; L, labrum; Lab, labrum.

Over the past 2 decades, interest has increased in anatomic variations in the proximal femur and acetabulum as they pertain to femoroacetabular impingement (FAI), labral pathology, and hip osteoarthritis. It is now recognized that decreased femoral head-neck offset is the primary cause of cam-type FAI.<sup>1,2</sup> In addition, acetabular overcoverage, which can either be focal from acetabular retroversion or global retroversion as seen in coxa profunda or protusio acetabuli, is the principal cause of pincer-type FAI.<sup>3-5</sup> Regardless of whether a patient has cam impingement, pincer impingement, or both, it is now believed that these variations are risk factors for early hip osteoarthritis. Many cases of hip osteoarthritis previously described as idiopathic may in fact be due to these subtle bony abnormalities.<sup>1,6</sup>

Although much attention has been given to variations in proximal femoral and acetabular anatomy, less attention has been focused on the role of femoral version. Alterations in femoral version have been associated with hip pain and osteoarthritis for more than 30 years.<sup>7-11</sup> It has been further speculated that excessive femoral anteversion or femoral retroversion may also play a role in the pathogenesis and treatment of FAI.<sup>1,12</sup>

The soft tissues around the hip are also important in the development of hip pathology. The iliopsoas muscle is the most important hip flexor. It has a close anatomic relationship with the acetabular labrum and the anterior capsule. This muscle has been associated with anterior hip pain in cases of flexor tendinitis, snapping hips, and psoas impingement.<sup>13</sup> Psoas impingement has been described as a cause of labral tears.<sup>14</sup> These tears can occur in a more anterior position (close to the psoas tendon) in patients with no bony abnormalities.<sup>14</sup>

The purpose of this study was threefold: (1) to describe values for femoral anteversion measured using magnetic resonance imaging (MRI) in patients un-

dergoing hip arthroscopy for FAI; (2) to report the relationship between physical examination findings and femoral version in these patients; and (3) to report the relationship between the degree of femoral anteversion and intraoperative findings during hip arthroscopy. The authors hypothesized that patients with significant variations in femoral version would have differing preoperative examination findings and intraoperative hip pathology.

## MATERIALS AND METHODS

Between June 2009 and May 2010, a total of 392 hip arthroscopies were performed at the authors' institution. Patients were included in this study if they had undergone hip arthroscopy for the treatment of FAI with concomitant labral pathology and had their femoral version measured by MRI preoperatively. Exclusion criteria included prior hip arthroscopy, age younger than 18 years, and hip dysplasia, defined as a lateral center-edge angle less than 20°.<sup>15</sup> This study was approved by the institutional review board.

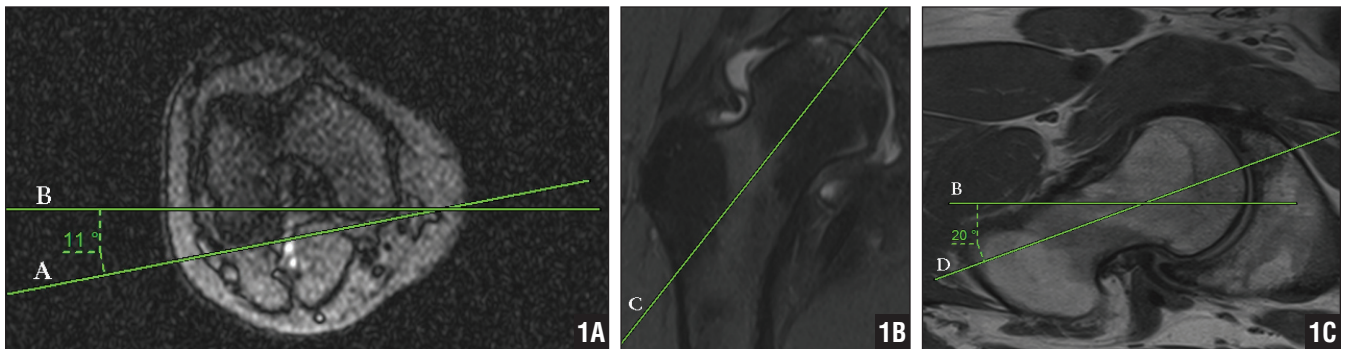
A total of 188 consecutive patients (204 hips) met the inclusion criteria. Patient demographics, including age, sex, weight, height, and body mass index, were prospectively collected and retrospectively reviewed. All patients underwent a detailed physical examination. Range of motion was measured with a goniometer in all planes, including abduction, adduction, flexion, and internal and external rotation. Internal and external rotation measurements were performed with the patient lying in the prone position on the examination table. The impingement test (flexion–adduction–internal rotation) and the flexion–adduction–internal rotation distance were also recorded. The flexion–adduction–internal rotation distance is determined by placing 1 leg in a figure-of-four position so the ipsilateral ankle is positioned proximal to the contralateral knee. The vertical distance between the genicular line and the examination table was recorded, and the difference between

the affected and nonaffected side was calculated. The test was positive when the difference between extremities was more than 4 cm.<sup>15</sup>

Radiographic views included an anteroposterior pelvic view, a cross-table lateral view, and a false-profile view. After radiographic evaluation, hips were classified as having either cam, pincer, or mixed-type (cam and pincer) impingement. Hips classified as having cam impingement had an alpha angle greater than 50°. Hips classified as having pincer impingement had at least 1 of the following radiographic findings: a crossover sign, coxa profunda, or protusio acetabuli. The alpha angle was measured in the cross-table lateral view as described by Nötzli et al.<sup>16</sup> The lateral center-edge angle was measured on the anteroposterior view.<sup>15</sup> The anterior center-edge angle was not measured.

Magnetic resonance imaging was obtained in all cases using a 3-T unit (Magnetom Verio 3T; Siemens Medical Systems, Erlangen, Germany). No arthrograms were performed. Images were evaluated for the presence of labral tears, cartilage disorders, ligamentum teres ruptures, and other soft tissue pathologies. The femoral anteversion was measured using the technique described by Tomczak et al.<sup>17</sup> After obtaining a scout view of the knee, an axial slice containing the most posterior aspect of both femoral condyles was determined, and an angle comprising the horizontal plane and a line containing the most posterior part of the distal femoral condyles was determined.

A second slice containing the center of the femoral head and the center of the femoral neck was obtained and considered to be the femoral neck axis. Then, an angle comprising the femoral neck and the horizontal plane was measured. The femoral neck anteversion angle was considered to be the difference between the femoral neck angle and the posterior distal condyle angle (Figure 1). Positive angles were considered anteversion and negative angles were con-



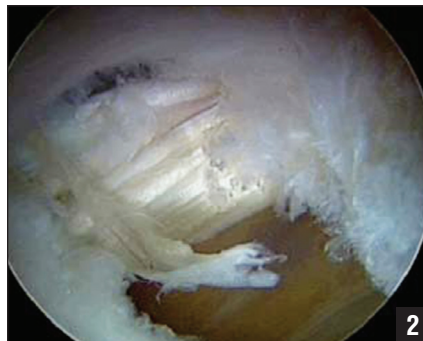
**Figure 1:** Scout view magnetic resonance image of the right knee showing the angle between the most posterior part of the femoral condyles (line A) and the horizontal plane (line B) (A). Plane containing the center of the femoral head and the center of the femoral neck (line C) (B). Slice in the plane in Figure 1B showing the angle comprising the center of the femoral neck and head (line D) and the horizontal plane (line B). In this example, the femoral neck version is  $9^\circ$  (angle in Figure 1C—angle in Figure 1A) (C).

sidered retroversion. All MRI data were analyzed by a fellowship-trained musculoskeletal radiologist (C.P.H.) with more than 10 years of clinical practice. Magnetic resonance imaging was obtained for the injured hip only.

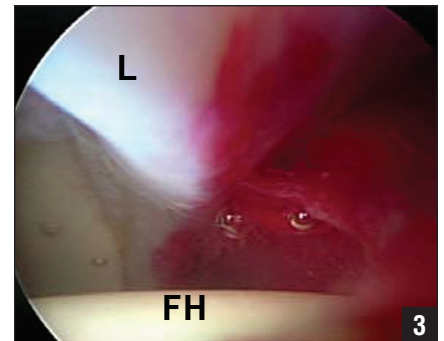
## SURGICAL TECHNIQUE

All hip arthroscopies were performed by the senior author (M.J.P.) with patients in the modified supine position on a fracture table using anterolateral and midanterior portals, as previously described.<sup>18,19</sup> Intraoperative data included the presence, location, and size of a labral tear, the presence and location of cartilage lesions, which were graded according to the Outerbridge classification,<sup>20</sup> the presence of ligamentum teres pathology, and the necessity for either an arthroscopic psoas release or a capsular plication. Patients with grade IV cartilage lesions underwent a microfracture procedure.

All ligamentum teres tears, both partial and complete, were treated with thermal and mechanical debridement. If a psoas release was necessary, it was performed in the central compartment through a small capsular window using an arthroscopic knife (Figure 2). This was a partial release, cutting only the tendinous part of the muscle–tendon unit of the iliopsoas muscle. Indications for a psoas release included internal snapping hip (asymptomatic or symptomatic), flexor tendinitis, and intense synovitis in the anterior capsule during hip arthroscopy (Figure 3). Flexor tendinitis was diagnosed by physical examination, which included tenderness associated with the psoas with palpation and painful resisted leg flexion, in addition to signs of edema in the flexor tendon on MRI. Synovitis of the anterior capsule next to the “psoas U” in patients with FAI was often associated with flexor tendinitis in the senior author’s experience.



**Figure 2:** Arthroscopic image showing psoas release performed in the central compartment through a small capsular window using an arthroscopic knife.

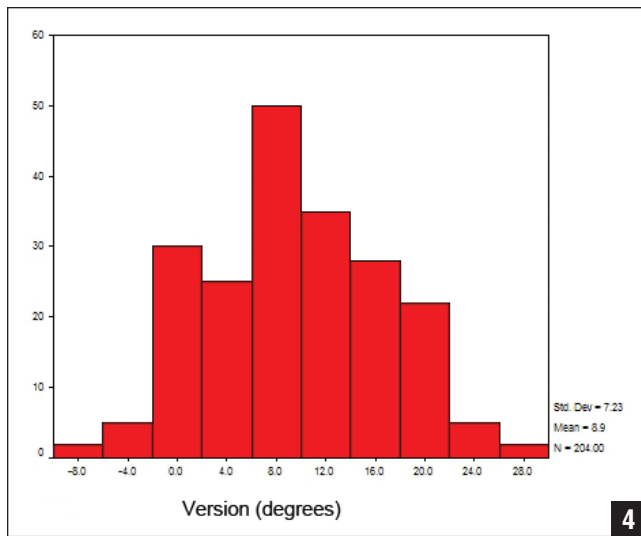


**Figure 3:** Arthroscopic image of intense synovitis in the anterior capsule in a patient who required psoas release. Abbreviations: FH, femoral head; L, labrum.

The senior author performed a capsular closure in the majority of hip arthroscopies and chose to perform a plication in cases of capsular laxity. Capsular laxity was considered in cases of global laxity (knee hyperextension and elbow hyperextension), in patients subjectively report-

ing hip instability, and in patients where a patulous capsule was observed during hip arthroscopy. Labral tears were repaired with suture anchors if possible. The size and location of the labral tears were recorded using the clock-face location system.<sup>21</sup> Labral tear size was estimated using a burr as a reference size. The same surgeon measured all tears with the same device. For the labral tear location analysis, all data on left hips were mirrored and presented as right hips. In cases where the labral tear was considered unreparable, a labral reconstruction using an iliotibial autograft was performed.<sup>22</sup>

Comparison of continuous variables by binary categorical variables was performed using the independent-samples *t* test, and comparison of multiple (more



**Figure 4:** Graph showing a normal femoral neck version distribution with the peak at 8°. Values less than 0 indicate retroversion. Abbreviation: Std Dev, standard deviation.

than 2) categorical variables was performed using 1-way analysis of variance. Comparison of 2 continuous variables was performed using Pearson's correlation coefficient. Comparison of categorical variables was performed using Fisher's exact test for comparisons of proportions. Statistical analyses were performed using SPSS version 11 statistical software (SPSS Inc, Chicago, Illinois). All reported *P* values are 2-tailed, with an alpha level of .05 indicating statistical significance.

**RESULTS**

The study group comprised 100 men and 88 women with a mean age of 35 years (range, 18 to 62 years). Mean patient height was 68 inches (range, 61 to 84 inches), mean weight was 165 lb (range, 110 to 318 lb), and mean body mass index was 24 kg/m<sup>2</sup> (range, 15 to 41 kg/m<sup>2</sup>).

Mean femoral anteversion angle was 9° (range, -10° to 27°). For statistical analysis, hips were divided into 3 groups: group 1 included hips with an anteversion angle of less than 5° (n=45; 22%), group 2 included hips with an anteversion angle between 5° and 15° (n=102;

50%), and group 3 included hips with an anteversion angle greater than 15° (n=57; 28%). Femoral version was normally distributed according to the Kolmogorov-Smirnov test (Figure 4). No relationship was found between patient demographics (ie, age, sex, height, weight, and body mass index) and femoral version angle. In the 16 bilateral patients, no statistical difference was found in the

femoral neck version between sides. The first operated side had an average of 8° of femoral version, and the second side had an average of 6° of femoral version (*P*=.134).

The physical examination revealed the following mean range of motion for the affected hip joint: abduction=45° (range, 18° to 95°), adduction=19° (range, 2° to 35°), flexion=109° (range, 45° to 145°), external rotation=40° (range, 2° to 96°), and internal rotation=25° (range, 3° to 95°). All hips had a positive impingement sign. Mean difference of the FABER distance between the affected and nonaffected sides was 4 cm (range, 0 to 26 cm). Seventy-two (35%) patients had a difference greater than 4 cm between sides and were considered to have a positive FABER test. A significant correlation was found between version degrees and degrees of external rotation (*r*=-0.208; *P*=.027) and internal rotation (*r*=0.231; *P*=.002). A significant difference existed between version groups based on external rotation (*P*=.027). External rotation for group 1 (average, 45°±14°) was significantly higher than that for groups 2 (average,

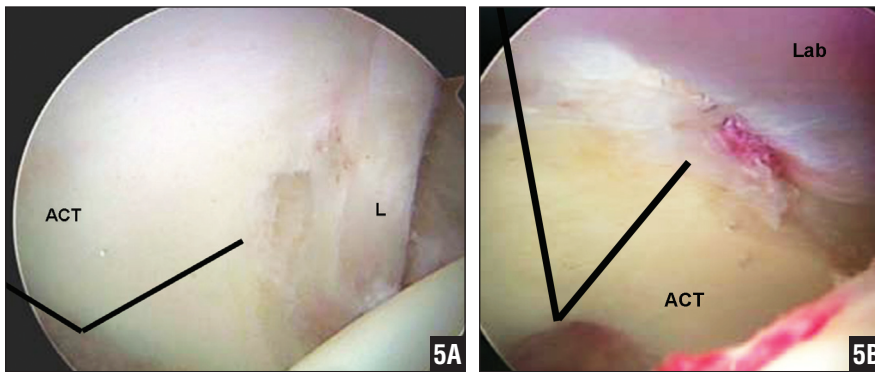
38°±12°) and 3 (average, 36°±13°). Average internal rotation was 23° for group 1, 25° for group 2, and 30° for group 3, but this was not statistically different.

After radiographic evaluation, 20% of hips were diagnosed with pincer impingement, 5% with cam impingement, and 75% with mixed-type impingement. Average lateral center-edge angle was 36° (range, 20° to 51°). Mean alpha angle was 70° (range, 41° to 99°). No significant correlation was found between alpha angle or center-edge angle and version.

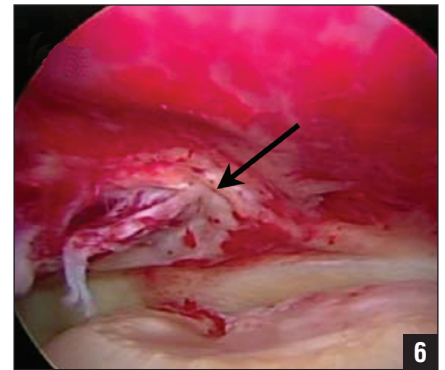
During hip arthroscopy, labral tears were identified in 88% of patients. Mean tear size was 34 mm (range, 10 to 72 mm). Mean tear size was 30 mm in group 1, 34 mm in group 2, and 38 mm in group 3 (*P*=.008). Regarding labral tear position, in hips with more than 15° of femoral anteversion, 26 tears extended past the 3-o'clock position and 33 did not; however, in hips with less than 15° of anteversion, 37 extended past the 3-o'clock position and 103 did not. Hips with anteversion angles greater than 15° were 2.2 times more likely to have labral tears that extended past the 3-o'clock position (95% confidence interval, 1.2 to 4.1), denoting more anterior tears (Figure 5). Labral repairs were performed in 178 patients and labral reconstructions in 13 patients.

Outerbridge grade III or IV cartilage lesions were identified in 97 (52%) hips on the femoral side (23 on the weight-bearing zone) and in 56 (30%) hips on the acetabular side. A microfracture was performed in 23 (12%) of these cases. The psoas tendon was arthroscopically released in 44 (21%) patients. Tears of the ligamentum teres, both full (3 hips) and partial (126 hips), were identified during 129 (63%) of the surgeries (Figure 6). A significant association was found between femoral version and the need for a psoas release. Mean femoral version angle was 11° in patients in whom a psoas release was performed and 8° in patients in whom a psoas release was not performed (*P*=.023). No asso-





**Figure 5:** Arthroscopic image of a labral tear in the anterior position extending past the 3-o'clock position (A) compared with a tear in the 12- to 2-o'clock position (B). Abbreviations: ACT, acetabulum; L, labrum; Lab, labrum.



**Figure 6:** Arthroscopic image showing a partial tear of the ligamentum teres (arrow).

ciation was found between the presence of grade III or IV cartilage lesions or ligamentum teres tears and femoral version.

## DISCUSSION

The results of this study revealed that patients undergoing hip arthroscopy for FAI had a mean femoral neck version of  $9^\circ$ . Although no relationship was found between femoral neck version and patient demographics, hip external rotation was negatively correlated with femoral version and internal rotation was positively correlated with femoral version. In addition, hips with greater anteversion were more likely to have larger and more anterior labral tears and to require a psoas tendon release at the time of arthroscopy.

Femoral neck version is the torsion of the proximal femoral head with reference to the distal femur.<sup>23</sup> When discussing femoral version, defining normal values is of paramount importance. The Table shows normal values reported in the literature. Values range from  $8^{\circ}$ <sup>23</sup> to  $20^{\circ}$ .<sup>7,12,17,24,25,37,51-61</sup> The current study found a mean femoral anteversion angle of  $9^\circ$ , which is consistent with the literature. Therefore, it appears that femoral version does not differ in the FAI population compared with healthy individuals. The current findings are also similar to the value of  $9.7^\circ$  found by Ito et al.<sup>12</sup> A broad range of values for femoral version (range,  $-10^\circ$  to  $27^\circ$ ) has been reported

in prior studies,<sup>23-39,51-61</sup> which makes it challenging to define a normal range for femoral version.

Several methods have been described to measure femoral version, including physical examination,<sup>26,27</sup> radiography,<sup>29,30</sup> ultrasonography,<sup>31-34</sup> two-dimensional computed tomography (CT),<sup>25,35-37</sup> three-dimensional CT<sup>23,38</sup> and MRI.<sup>17,39</sup> Magnetic resonance imaging has the advantage over radiography and CT of avoiding radiation exposure. Moreover, MRI is used routinely in FAI patients to evaluate labral and cartilage pathology.<sup>40,41</sup> Although CT scans remain the gold standard for calculating femoral version, studies with MRI have reported high levels of accuracy compared with CT scans with high inter- and intraobserver agreements.<sup>17</sup>

In the current study, no relationship was identified between patient demographics (ie, age, sex, weight, height, and body mass index) and femoral version. However, a correlation was found between femoral version and hip external rotation. In addition, the data showed that external rotation increased for patients with femoral version less than  $5^\circ$ . No difference was found between the other groups. For internal rotation, a statistically significant difference did not exist between the groups, so it was unclear at what degree of version internal rotation is diminished. This relationship has been previously described in the literature<sup>42,43</sup> and is used to estimate femoral

neck version during physical examination. This is an important finding because symptomatic FAI patients typically have decreased range of motion,<sup>15,44</sup> so the relation between hip ROM and femoral neck version could be lost in patients with FAI. However, physical examination in the current study was performed while patients were awake, so it is impossible to estimate if rotation was limited by pain and not just by bony impingement.

During hip arthroscopy, patients with femoral anteversion greater than  $15^\circ$  had larger labral tears than patients with femoral anteversion less than  $15^\circ$ . Patients with higher anteversion also had labral tears located in a more anterior location. In addition, hips that needed a psoas release had greater anteversion compared with those that did not. Psoas impingement is caused by a compression or traction force of the psoas tendon on the anterior capsulolabral complex.<sup>41</sup> This force may lead to more anterior labral tears that occur in close proximity to the psoas valley, or psoas U.<sup>45</sup> The relationship of the psoas muscle and femoral anteversion has been previously described in the literature. Using a mathematical model, Frain<sup>46</sup> reported that when femoral anteversion is marked, the anterior muscles play a greater role in the maintenance of equilibrium. Schutte et al<sup>47</sup> used a computerized model to show that psoas muscle length is sensitive to femoral anteversion. Greater antever-

Table

Femoral Neck Version Values in the Literature

Study	Study Method	No. of Femurs	Average ± SD (Range) Femoral Neck Version, deg
Current study	MRI	204	9 (27 to -10)
Reikerås et al <sup>7</sup>	CT	47	13 ± 7
Ito et al <sup>12</sup>	MRI in controls	24	15.7 ± 4.4
	MRI in patients with FAI	24	9.7 ± 4.7
Tomczak et al <sup>17</sup>	CT	25	22.2 ± 9.4
	MRI	25	15.71 ± 9.3
Kingsley & Olmsted <sup>24</sup>	Anatomic	630	8 (38 to -20)
Sugano et al <sup>25</sup>	3-D CT on specimens	30	19.8 ± 9.3
Reikerås et al <sup>37</sup>	Anatomic	96	10.4 ± 6.7
Soutter & Bradford <sup>51</sup>	Anatomic	154	14.3 (50 to 0)
Parsons <sup>52</sup>	Anatomic	300	15.5 (40 to -17)
Durham <sup>53</sup>	Anatomic	200	11.9 (35 to 0)
Pick et al <sup>54</sup>	Anatomic	152	14 (41 to -18)
Gray <sup>55</sup>	N/A	N/A	(14 to 12)
Dunlap et al <sup>56</sup>	Radiographs	200	8.7
Alvik <sup>57</sup>	N/A	N/A	12
Bauman et al <sup>58</sup>	Weighted average from literature	1436	11.4 (50 to -20)
Wasielowski <sup>59</sup>	N/A	N/A	15
Koval & Zuckerman <sup>60</sup>	N/A	N/A	10
Toogood et al <sup>61</sup>	Anatomic	375	9.73 ± 9.28 (35.9 to -14.63)

Abbreviations: 3-D, 3-dimensional; CT, computed tomography; deg, degrees; MRI, magnetic resonance imaging; N/A, not available.

sion angles may lead to an overtightened psoas. It is unclear how large of an increase in version angle would be necessary to cause the psoas to require treatment. In a recent study, increased femoral version was associated with inferior outcomes after psoas lengthening.<sup>48</sup> However, it is important to note that increased femoral version was greater than 25° in that study. However, in the current study, only 2 patients had femoral version greater than 25°. Further research is needed to better elucidate the relationship of the psoas tendon, femoral version, and acetabular labrum.

Femoral version influencing hip pathology is not a novel idea; however, reports are contradictory regarding whether higher or lower angles are detrimental for the hip joint. In osteoarthritis, both increased and decreased femoral anteversion have been implicated in primary osteoarthritis of the hip.<sup>7-11,49,50</sup> Regarding FAI, decreased femoral version has been reported as a predisposing factor in the pathomechanics of impingement.<sup>1,12</sup> The current study demonstrated that patients with FAI can present with normal, increased, or decreased femoral anteversion.

Limitations to the current study included its retrospective design and the lack of a control group to compare the values of femoral anteversion. Nevertheless, a thorough literature review provided an adequate historical control group for comparison of femoral version. Another limitation to the study was the referral nature of the study population. The majority of the patients were seen by other practitioners and referred to the current authors' institution for surgical treatment. This explains the large number of patients with FAI and the high percentage of patients with labral tears. To the authors' knowledge, this was the first study to evaluate the association of femoral anteversion with intraoperative findings in patients with FAI and was the largest series of patients in the literature with femoral version measurements on MRI.

CONCLUSION

In the current study, patients with FAI had a mean anteversion angle of 9°, which is similar to values found in the normal population. No relationship was found between femoral version and patient demographics, but a correlation was identified between femoral neck version and hip rotation. Hips with increased femoral version angles had larger and more anterior labral tears during hip arthroscopy. Femoral neck version should be taken into consideration in FAI treatment.

REFERENCES

- Ganz R, Parvizi J, Beck M, Leunig M, Notzli H, Siebenrock KA. Femoroacetabular impingement: a cause for osteoarthritis of the hip. *Clin Orthop Relat Res.* 2003; 417:112-120.
- Beck M, Kalhor M, Leunig M, Ganz R. Hip morphology influences the pattern of damage to the acetabular cartilage: femoroacetabular impingement as a cause of early osteoarthritis of the hip. *J Bone Joint Surg Br.* 2005; 87:1012-1018.
- Reynolds D, Lucas J, Klauke K. Retroversion of the acetabulum. A cause of hip pain. *J Bone Joint Surg Br.* 1999; 81:281-288.
- Jamali AA, Mladenov K, Meyer DC, et al. Anteroposterior pelvic radiographs to assess acetabular retroversion: high validity of the "cross-over-sign". *J Orthop Res.* 2007; 25:758-765.

5. Kalberer F, Sierra RJ, Madan SS, Ganz R, Leunig M. Ischial spine projection into the pelvis: a new sign for acetabular retroversion. *Clin Orthop Relat Res.* 2008; 466:677-683.
6. McCarthy JC, Noble PC, Schuck MR, Wright J, Lee J. The Otto E. Aufranc Award: the role of labral lesions to development of early degenerative hip disease. *Clin Orthop Relat Res.* 2001; 393:25-37.
7. Reikerås O, Bjerkreim I, Kolbenstvedt A. Anteversion of the acetabulum and femoral neck in normals and in patients with osteoarthritis of the hip. *Acta Orthop Scand.* 1983; 54:18-23.
8. Tönnis D, Heinecke A. Acetabular and femoral anteversion: relationship with osteoarthritis of the hip. *J Bone Joint Surg Am.* 1999; 81:1747-1770.
9. Giunti A, Moroni A, Olmi R, Rimondi E, Soldati D, Vicenzi G. The importance of the angle of anteversion in the development of arthritis of the hip. *Ital J Orthop Traumatol.* 1985; 11:23-27.
10. Reikerås O, Høiseth A. Femoral neck angles in osteoarthritis of the hip. *Acta Orthop Scand.* 1982; 53:781-784.
11. Terjesen T, Benum P, Anda S, Svenningsen S. Increased femoral anteversion and osteoarthritis of the hip joint. *Acta Orthop Scand.* 1982; 53:571-575.
12. Ito K, Minka MA, Leunig M, Werlen S, Ganz R. Femoroacetabular impingement and the cam-effect. A MRI-based quantitative anatomical study of the femoral head-neck offset. *J Bone Joint Surg Br.* 2001; 83:171-176.
13. Philippon MJ, Maxwell RB, Johnston TL, Schenker M, Briggs KK. Clinical presentation of femoroacetabular impingement. *Knee Surg Sports Traumatol Arthrosc.* 2007; 15:1041-1047.
14. Domb BG, Shindle MK, McArthur B, Voos JE, Magennis EM, Kelly BT. Iliopsoas impingement: a newly identified cause of labral pathology in the hip. *HSS J.* 2011; 7:145-150.
15. Wiberg G. Studies on dysplastic acetabula and congenital subluxation of the hip joint. *Acta Chir Scand.* 1939; 83:5-135.
16. Nötzli HP, Wyss TF, Stoecklin CH, Schmid MR, Treiber K, Hodler J. The contour of the femoral head-neck junction as a predictor for the risk of anterior impingement. *J Bone Joint Surg Br.* 2002; 84:556-560.
17. Tomczak RJ, Guenther KP, Rieber A, Mergo P, Ros PR, Brambs HJ. MR imaging measurement of the femoral antetorsional angle as a new technique: comparison with CT in children and adults. *AJR Am J Roentgenol.* 1997; 168:791-794.
18. Philippon MJ, Schenker ML. A new method for acetabular rim trimming and labral repair. *Clin Sports Med.* 2006; 25:293-297.
19. Kelly BT, Weiland DE, Schenker ML, Philippon MJ. Arthroscopic labral repair in the hip: surgical technique and review of the literature. *Arthroscopy.* 2005; 21:1496-1504.
20. Outerbridge RE. The etiology of chondromalacia patellae. *J Bone Joint Surg Br.* 1961; 43:752-757.
21. Philippon MJ, Stubbs AJ, Schenker ML, Maxwell RB, Ganz R, Leunig M. Arthroscopic management of femoroacetabular impingement: osteoplasty technique and literature review. *Am J Sports Med.* 2007; 35:1571-1580.
22. Philippon MJ, Briggs KK, Hay CJ, Kupper-Smith DA, Dewing CB, Huang MJ. Arthroscopic labral reconstruction in the hip using iliotibial band autograft: technique and early outcomes. *Arthroscopy.* 2010; 26:750-756.
23. Kim JS, Park TS, Park SB, Kim JS, Kim IY, Kim SI. Measurement of femoral neck anteversion in 3D. Part 1: 3D imaging method. *Med Biol Eng Comput.* 2000; 38:603-609.
24. Kingsley PC, Olmsted KL. A study to determine the angle of anteversion of the neck of the femur. *J Bone Joint Surg Am.* 1948; 30:745-751.
25. Sugano N, Noble PC, Kamaric E. A comparison of alternative methods of measuring femoral anteversion. *J Comput Assist Tomogr.* 1998; 22:610-614.
26. Ruwe PA, Gage JR, Ozonoff MB, DeLuca PA. Clinical determination of femoral anteversion. A comparison with established techniques. *J Bone Joint Surg Am.* 1992; 74:820-830.
27. Davids JR, Benfanti P, Blackhurst DW, Allen BL. Assessment of femoral anteversion in children with cerebral palsy: accuracy of the trochanteric prominence angle test. *J Pediatr Orthop.* 2002; 22:173-178.
28. Hermann KL, Egund N. Measuring anteversion in the femoral neck from routine radiographs. *Acta Radiol.* 1998; 39:410-415.
29. Kuo TY, Skedros JG, Bloebaum RD. Measurement of femoral anteversion by biplane radiography and computed tomography imaging: comparison with an anatomic reference. *Invest Radiol.* 2003; 38:221-229.
30. Lee DY, Lee CK, Cho TJ. A new method for measurement of femoral anteversion. A comparative study with other radiographic methods. *Int Orthop.* 1992; 16:277-281.
31. Berman L, Mitchell R, Katz D. Ultrasound assessment of femoral anteversion. A comparison with computerised tomography. *J Bone Joint Surg Br.* 1987; 69:268-270.
32. Lausten GS, Jørgensen F, Boesen J. Measurement of anteversion of the femoral neck. Ultrasound and computerised tomography compared. *J Bone Joint Surg Br.* 1989; 71:237-239.
33. Moulton A, Upadhyay SS. A direct method of measuring femoral anteversion using ultrasound. *J Bone Joint Surg Br.* 1982; 64:469-472.
34. Terjesen T, Anda S. Femoral anteversion in children measured by ultrasound. *Acta Orthop Scand.* 1987; 58:403-407.
35. Murphy SB, Simon SR, Kijewski PK, Wilkinson RH, Griscom NT. Femoral anteversion. *J Bone Joint Surg Am.* 1987; 69:1169-1176.
36. Weiner DS, Cook AJ, Hoyt WA, Oravec CE. Computed tomography in the measurement of femoral anteversion. *Orthopedics.* 1978; 1:299-306.
37. Reikerås O, Høiseth A, Reigstad A, Fonstelién E. Femoral neck angles: a specimen study with special regard to bilateral differences. *Acta Orthop Scand.* 1982; 53:775-779.
38. Abel MF, Sutherland DH, Wenger DR, Mubarak SJ. Evaluation of CT scans and 3-D reformatted images for quantitative assessment of the hip. *J Pediatr Orthop.* 1994; 14:48-53.
39. Guenther KP, Tomczak R, Kessler S, Pfeiffer T, Puhl W. Measurement of femoral anteversion by magnetic resonance imaging-evaluation of a new technique in children and adolescents. *Eur J Radiol.* 1995; 21:47-52.
40. Philippon MJ, Schenker ML. Arthroscopy for the treatment of femoroacetabular impingement in the athlete. *Clin Sports Med.* 2006; 25:299-308.
41. Shindle MK, Voos JE, Nho SJ, Heyworth BE, Kelly BT. Arthroscopic management of labral tears in the hip. *J Bone Joint Surg Am.* 2008; 90:2-19.
42. Staheli LT, Duncan WR, Schaefer E. Growth alterations in the hemiplegic child. A study of femoral anteversion, neck-shaft angle, hip rotation, C.E. angle, limb length and circumference in 50 hemiplegic children. *Clin Orthop Relat Res.* 1968; 60:205-212.
43. Chung CY, Lee KM, Park MS, Lee SH, Choi IH, Cho TJ. Validity and reliability of measuring femoral anteversion and neck-shaft angle in patients with cerebral palsy. *J Bone Joint Surg Am.* 2010; 92:1195-1205.
44. Wyss TF, Clark JM, Weishaupt D, Notzli HP. Correlation between internal rotation and bony anatomy in the hip. *Clin Orthop Relat Res.* 2007; 460:152-158.
45. Vandenbussche E, Saffarini M, Taillieu F, Mutschler C. The asymmetric profile of the acetabulum. *Clin Orthop Relat Res.* 2008; 466:417-423.
46. Frain P. Mechanical effects of femoral anteversion of the hip. Assessment of the validity of Pauwels' theory. *Rev Chir Orthop Reparatrice Appar Mot.* 1981; 67:1-9.
47. Schutte LM, Hayden SW, Gage JR. Lengths of hamstrings and psoas muscles during crouch gait: effects of femoral anteversion. *J Orthop Res.* 1997; 15:615-621.

48. Fabricant PD, Bedi A, De La Torre K, Kelly BT. Clinical outcomes after arthroscopic psoas lengthening: the effect of femoral version. *Arthroscopy*. 2012; 28:965-971.
49. Solomon L. Patterns of osteoarthritis of the hip. *J Bone Joint Surg Br*. 1976; 58:176-183.
50. Tönnis D, Heinecke A. Diminished femoral antetorsion syndrome: a cause of pain and osteoarthritis. *J Pediatr Orthop*. 1991; 11:419-431.
51. Soutter R, Bradford EH. Twists in normal and congenitally dislocated femora. *New York Med J*. 1903; 78:1071-1077.
52. Parsons FG. The characters of the English thigh-bone. *J Anat Physiol*. 1914; 48:238-267.
53. Durham HA. Anteversion of the femoral neck in the normal femur and its relation to congenital dislocation of the hip. *JAMA*. 1915; 65:223-224.
54. Pick JS, Stack JK, Anson BJ. Measurements on the human femur. Lengths, diameters and angles. Quarterly Bulletin of Northwestern University Medical School. 1941; 15:281-290.
55. Gray H. Anatomy of the human body. In: Warren H, ed. *Osteology*. Philadelphia, PA: Lea and Febiger; 1942:234.
56. Dunlap K, Shands AR, Hollister LC, Gaul JS, Streit HA. A new method for determination of torsion of the femur. *J Bone Joint Surg Am*. 1953; 35:289-311.
57. Alvik I. Increased anteversion of the femur as the only manifestation of dysplasia of the hip. *Clin Orthop Relat Res*. 1962; 22:16-20.
58. Bauman PA, Singson R, Hamilton WG. Femoral neck anteversion in ballerinas. *Clin Orthop Relat Res*. 1994; 302:57-63.
59. Wasielewski RC. The hip. In: Callaghan JJ, Rosenberg AG, Rubash HE, eds. *The Adult Hip*. Philadelphia, PA: Lippincott Williams & Wilkins; 2006:51-67.
60. Koval K, Zuckerman J. *Handbook of Fractures*. Philadelphia, PA: Lippincott Williams & Wilkins; 2006.
61. Toogood PA, Skalak A, Cooperman DR. Proximal femoral anatomy in the normal human population. *Clin Orthop Relat Res*. 2009; 467:876-885.